

Cornell University  
Veterinary Specialists  
**ADVANCE2025**

Feline Chronic Gingivostomatitis  
is sponsored by  
**IDEXX**

---

---

---

---

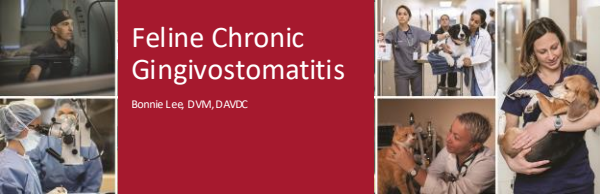
---

---


---

---

Feline Chronic  
Gingivostomatitis  
Bonnie Lee DVM, DAVDC



Cornell University  
Veterinary Specialists



---

---

---

---

---

---

---

---

**Outline**

---

Feline Chronic Gingivostomatitis (FCGS)

- Clinical picture
- Formulate a thorough diagnostic plan
- Step-wise treatment options
- Prognosis

Cornell University Veterinary Specialists

---

---

---

---

---

---

---

---

### Clinical Picture

- Drooling
- Bleeding from the mouth
  - Blood-tinged stool, blood on fur (chest, thoracic limbs)
- Bad breath
- Decreased grooming
- Changes in eating or trouble chewing
  - Eating less, dropping food, preferring soft food, weight loss
  - Showing an interest in food but vocalizing and running away after attempting to eat
- Changes in play or desire to play
- Changes in behavior
  - Reluctance to be touched on the face or around the mouth, decreased energy level, decreased socialization with the family

This clinical picture is not specific to FCGS, so we need to perform a thorough oral exam along with additional diagnostics

Cornell University Veterinary Specialists

---

---

---

---




---

---

---

---

### Clinical Picture

-  These cats are painful
-  Provide supportive care
-  Prescribe analgesia

Cornell University Veterinary Specialists

---

---

---

---

---

---

---

---

### Awake oral exam

- Visual assessment of facial symmetry
- Palpate facial symmetry
  - Muscles of mastication, periauricular, orbits, zygomas, lateral and ventral mandibles, intermandibular space
  - Mandibular lymph nodes and salivary glands
- Bilateral digital retro-pulsion of the globes
- Labial and buccal mucosa and gingiva
- Teeth
- Open mouth
  - Palate, tongue, sublingual tissues, vertical mandibular range of motion

Cornell University Veterinary Specialists

---

---

---

---

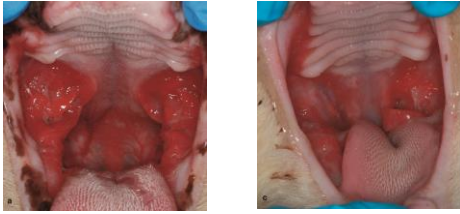
---

---

---

---

### Awake oral exam



Bilaterally symmetric mild to moderate mandibular lymphadenopathy

1. Salem-Riwan H, Gabelchack S, Arz B. 2013

Cornell University Veterinary Specialists

---

---

---

---

---

---

---

---

### Differentials

- Differentials
  - Uremic ulceration
  - Neoplasia
    - Lymphoma
    - Squamous cell carcinoma
  - Eosinophilic granuloma complex
  - Contact ulceration
  - Autoimmune disease
- Different distribution of inflammation
  - Early onset gingivitis
  - Aggressive periodontitis

Cornell University Veterinary Specialists

---

---

---

---

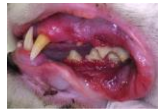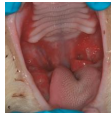---

---

---

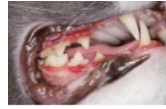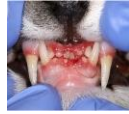---

### FCGS



• Often mature adults

### Early onset gingivitis



• Often apparent at 6-8 months of age

1. Salem-Riwan H, Nagaraja M, Rivera L, Arz B. 2013  
2. Anderson JC. 2011

Cornell University Veterinary Specialists

---

---

---

---

---

---

---

---

### Bloodwork

- Complete blood count
  - Anemia
  - Leukocytosis due to neutrophilia
- Serum biochemistry
  - Hyperglycemia
  - Hyperglobulinemia
- FIV/FeLV (could inform prognosis)
- FCV (could inform future medical management)
- PFFV (largely academic at this time)

1. Vignati M, N. J. Simpson DL, Ar. B. B. T. K. H. G. N. W. A. K. N. J. G. C. C. B. K. K. Y. E. B. S. P. A. S. S. I. D. L. 2003  
2. S. A. S. M. W. N. H. G. O. B. C. H. I. N. S. A. R. A. B. 2013

Cornell University Veterinary Specialists

---

---

---

---

---

---

---

---

### Incisional biopsy

- Atypical FCGS presentation or lesion asymmetry
  - Biopsy prior to extractions
  - Incisional biopsy of presumed mucositis
- Classic FCGS presentation and lesion symmetry
  - Biopsy at the time of extractions
  - Incisional biopsy of gingiva and mucosa adjacent to quadrant flap incisions
- Heavy infiltration of lymphocytes and plasma cells

1. S. A. S. M. W. N. H. G. O. B. C. H. I. N. S. A. R. A. B. 2013

Cornell University Veterinary Specialists

---

---

---

---

---

---

---

---

### What do we know about it?

- Immune-mediated inflammatory disease
  - We do not fully understand the disease process
- Predominance of CD8+ T cells in stomatitic lesions and as circulating effector memory cells
  - Implicates cytotoxic immunity against an intracellular pathogen such as a virus
- Evidence of systemic inflammation with pro-inflammatory cytokines and blood neutrophilia

1. S. A. S. M. W. N. H. G. O. B. C. H. I. N. S. A. R. A. B. 2013

Cornell University Veterinary Specialists

---

---

---

---

---

---

---

---

### What do we know about it?

- Increasing suspicion for chronic FCV infection
    - No direct causal relationship has been established
  - ✓ Metagenomic and transcriptome analysis revealed a strong correlation between FCV and FCGS
    - 21/23 FCGS cats were FCV+
    - No control cats were FCV+
  - ✓ At least some FCV+ cats have decreased FCV shedding, FCV load or FCV resolution with resolution of FCGS
- X In another study of FCV+ cats, FCV load was not correlated with the severity of oral lesions or outcome following extractions

1. Friel WA, Sidani-Razin M, Rumbak A, Lommer PJ, Aris B, D'Almeida J, Haines JA. 2022  
 2. Adriaens D, Kaeberlein A, Yoon PS, Taylor DJ. 2019  
 3. Dixon LM. 2017

Cornell University Veterinary Specialists

---

---

---

---

---

---

---

---

---

---

### What do we know about it?

- Cats with FCGS are more likely to come from shared households compared with control cats
- Cats with FCGS have significantly more cats per household compared with control cats
- Cats in multi-cat households have significantly increased odds of having FCGS compared with those in single-cat households

1. Pedro S. 2017

Cornell University Veterinary Specialists

---

---

---

---

---

---

---

---

---

---

### Treatment

- |   |          |   |
|---|----------|---|
| <p><b>1. Surgical Management</b></p> <ul style="list-style-type: none"> <li>• Extractions           <ul style="list-style-type: none"> <li>• Full vs partial mouth</li> </ul> </li> </ul> | <p>→</p> | <p><b>2. Medical Management</b></p> <ul style="list-style-type: none"> <li>• Immunosuppression</li> <li>• Immunomodulation</li> </ul> |
|---|----------|---|

Medical management without surgical management provides only temporary improvement at most, but can be used for a period if clients are saving to afford extractions

Cornell University Veterinary Specialists

---

---

---

---

---

---

---

---

---

---

### Extractions

The most effective initial treatment, but it is unclear how it works

**Do**

- Take photos to track changes
- Extract all teeth and tooth roots
- Always confirm complete extraction with dental radiographs
- Consider staging or referring

**Do not**

- Crown amputate and leave identifiable tooth material

Cornell University Veterinary Specialists

---

---

---

---

---

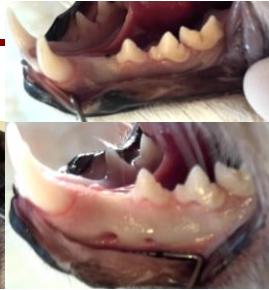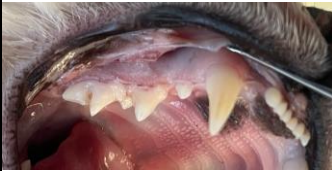---

---

---

### Extractions

Create and elevate quadrant flaps



Cornell University Veterinary Specialists

---

---

---

---

---

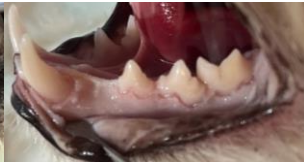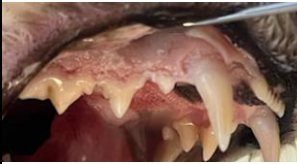---

---

---

### Extractions

Remove buccal bone



- Remove more if external replacement root resorption

Cornell University Veterinary Specialists

---

---

---

---

---

---

---

---

### Extractions

Section multi-rooted teeth



- "Moat" to luxate or elevate root tips as needed

Cornell University Veterinary Specialists

---

---

---

---

---


---

---

---

### Extractions

Luxate or elevate tooth roots with 1.35 or other hand instrument



Extract with extraction forceps

Cornell University Veterinary Specialists

---

---

---

---

---

---

---

---

### Extractions

Osteoplasty with a football or large round diamond bur



Cornell University Veterinary Specialists

---

---

---

---

---

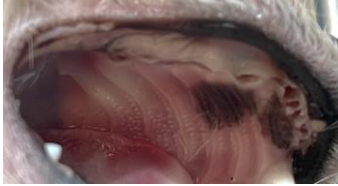---

---

---

### Extractions

Release the periosteum and trim inflamed and friable flap edges



Cornell University Veterinary Specialists

---

---

---

---

---

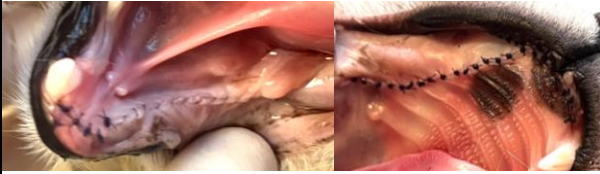
---

---

---

### Extractions

Close with 5-0 Monocryl in a simple interrupted vs simple continuous pattern



Cornell University Veterinary Specialists

---

---

---

---

---

---

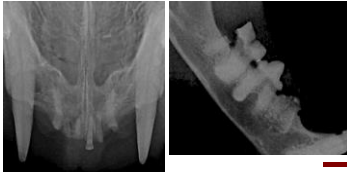---

---

### Extractions

Cats	External Inflammatory Tooth Resorption	Retained Tooth Roots
FCGS	49%	56%
Non-FCGS controls	25%	28%

\*significant difference



Cornell University Veterinary Specialists

1. Fava N, Lommer PJ, Kae P, Verstraete FJ 2014

---

---

---

---

---

---

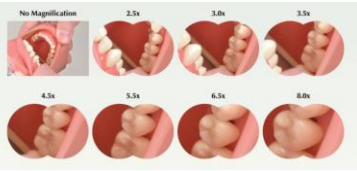
---

---

### Extractions

Helpful tools include loupes and suction

- Visualization
- Ergonomics



Cornell University Veterinary Specialists

1. <https://www.vetpractice.com/what-is-the-right-magnification-for-you/>

---

---

---

---

---

---

---

---

### Extractions

- Partial mouth extractions (PME)
  - Only teeth with stomatitic lesions, severe periodontitis, or tooth resorptive lesions are extracted
  - Often all premolars and molars
- PME vs full mouth extractions (FME)
  - Not associated with response to treatment
- Persistent stomatitic lesions following partial mouth extractions?
  - Extract remaining teeth

Cornell University Veterinary Specialists

1. <http://www.kittylou.com/>

---

---

---

---

---

---

---

---

### E-tube

Provide nutrition and medication while bypassing the oral cavity



Cornell University Veterinary Specialists

1. <https://www.kittylou.com/>

---

---

---

---

---

---

---

---

### Post-operative Medication

- Analgesia (until recheck)
  - NSAID
    - Steroid if preexisting medication or pharyngeal swelling
  - Buprenorphine
    - Fentanyl transdermal patch
  - Amantadine
  - Gabapentin
- Antibiotic (3-5 days)
  - Clavamox
  - Clindamycin

1. Stepien-Riewa M, Gabelnick S, Aron B. 2013

---

---

---

---

---

---

---

---

### Prognosis

Significant improvement to cure: ~67-80%

Publication	Clinical cure	Significant improvement	Little improvement	No improvement
Henret, 1997	60%	20%	13%	7%
Bellei, 2008	60%	20%	13%	7%
Jennings, 2015	28%	39%	27%	6%

1. Henne P. 1997

2. Bellei G, Kelly M, Hill L, Poon L, Jankov M. 2008

3. Jennings JW, Lutz MB, Brown B, Hill B, Boudreau S, et al. 2015

---

---

---

---

---

---

---

---

### Prognosis

Viral Status	Significant improvement to clinical cure	Little to no improvement
FIV- and FeLV-	90%	10%
FIV+	79%	21%
FeLV+	55%	45%

- FeLV+
  - Significantly worst response to dental extractions compared with FIV- and FeLV- cats
  - 7.5 times more chances of having no improvement with dental extractions compared with FIV- and FeLV- cats

1. Silva M, Fernandes M, Faife H, Monteiro L. 2021

---

---

---

---

---

---

---

---

## Prognosis

1. Post-extraction recheck at 2 weeks to evaluate surgical site healing
  - Better long-term response with resolution of abnormal behavior (OR 7.2) and decrease in inflammation (OR 3.5) at 2-4 weeks post-extraction
2. Recheck every 4 weeks thereafter to evaluate stomatitis inflammation and adjust medications

\*More frequent on an individual basis

1. Jenting HW, Lewis JR, Saloni-Rosen HR, Brown DC, Fox AL. 2015

---

---

---

---

---

---

---

---

## Extended Medical Management Immunosuppression

1. Prednisolone
  - 1mg/kg PO q12h
  - Tapering course, not for long-term use
2. Cyclosporine
  - 2.5mg/kg PO q12h

Medication	% Improvement	% cat with >40% Improvement	Blood trough cyclosporine	% Improvement
Cyclosporine	52%	77%	>300 ng/mL	72%
Placebo	12%	14%	<300ng/mL	28%

• 45% cured and cyclosporine discontinued at 3 months

1. Saloni-Rosen H, Goldschmidt S, Arath B. 2012  
2. Lommer PJ. 2010

---

---

---

---

---

---

---

---

## Treating refractory patients Immunomodulation with interferon omega

Delivery method	Interferon omega	Steroid
Daily oromucosal for 90 days in FCV positive cats	-Significant improvement in lesions and pain -45% significant improvement/cure -33% needed rescue medication	-No significant improvement in lesions and pain -23% significant improvement/cure -60% needed rescue medication
Submucosal injection 8x/4wk in FCV positive cats?	-Significant improvement in lesions and symptoms -Inhibited FCV proliferation	-No significant improvement in lesions and symptoms -Did not inhibit FCV proliferation

Interferon omega is not available in the US, so it must be imported from Europe and pass through customs without a break in the cold chain

1. Haines PL, Cheng GA, Haggan DR. Abstr. 2011  
2. Haggan DR, Taylor T, Bales T, Saloni-Rosen H, Saloni-Rosen H, Anderson A, Fox AL. 2011

---

---

---

---

---

---

---

---



## Summary

- FCGS is a painful immune-mediated disease
- FCV may have a role in the disease process
- Extraction is the recommended treatment with 67-80% of cats experiencing significant improvement to clinical cure
- Refractory cases may benefit from immunosuppressive or immunomodulatory treatment

Cornell University Veterinary Specialists

## References

1. Solter o-Riveva M, Goldschmidt S, Arz J, B. Feline chronic gingivostomatitis: current and potential clinical management. *J Feline Med Surg*. 2022 3 Aug;24(8):10996-129. 23118634. doi: 10.1177/1099612X21118634. PMID: 37548475.
2. Solter o-Riveva M, Vapnirky N, Riva R, Arz J. Clinical, radiographic and histopathologic aspects of early-onset gingivitis and periodontitis in cats [1997-2022]. *J Feline Med Surg*. 2023 Jan;25(1):10986-12X221148377. doi: 10.1177/1099612X221148377. PMID: 36653928.
3. Anderson JC, Hennet P. Management of Severe Oral Inflammatory Conditions in Dogs and Cats. *Vet Clin North Am Small Anim Pract*. 2022 Jan;25(1):159-184. doi: 10.1016/j.cvsm.2021.09.008. PMID: 34838249.
4. Vapnirky N, Simpson DA, Arz J, Tseehang N, Walker N, Gerriyc, Bukaley E, Borjesson DJ. Histological, immunological, and genetic aspects of feline chronic gingivostomatitis. *Front Vet Sci*. 2020 Jun 9;7:1310. doi: 10.3389/fvet.2020.00310. PMID: 32582783; PMCID: PMC7235054.
5. Fiedl W, Solter o-Riveva M, Ramech A, Lommer M, Arz J, Orlitz B, Hovest A. Use of unbiased metagenomic and transcriptomic analyses to investigate the association between feline calicivirus and feline chronic gingivitis stomatitis in domestic cats. *Am J Vet Res*. 2022 May;83(5):881-894. doi: 10.2460/ajvr.83.5.881. PMID: 35067979.
6. Adde DA, Radford A, Yam PS, Taylor DJ. Cessation of feline calicivirus shedding coincides with resolution of chronic gingivostomatitis in cats. *Small Anim Clin Pract*. 2023 Apr;44(4):212-16. doi: 10.1111/j.1365-3113.2022.1000104.x. PMID: 35703869.
7. Duest L, Hennet P. Relationship between Feline Infectious Leukemia, Oral Lesions, and Outcome in Feline Chronic Gingivostomatitis. *Open Access J Dent*. 2022;1(1):1-10. doi: 10.21203/3.1000001. PMID: 35704522; PMCID: PMC9249315.
8. Penati S, Farney PC. Feline chronic gingivostomatitis is more prevalent in shared households, and its risk correlates with the number of cats living in the cat's home. *Front Vet Sci*. 2017 Dec 5;4:2039. doi: 10.3389/fvet.2017.00209. PMID: 29270422; PMCID: PMC5749315.
9. Faraci N, Lommer M, Kasi P, Vapnirky N, Fiedl W, Goldschmidt S, Arz J. Feline chronic gingivostomatitis (FCGS) in cats. *J Am Vet Med Assoc*. 2014 Feb 1;244(3):333-40. doi: 10.2460/javma.244.3.333. PMID: 24423296.

Cornell University Veterinary Specialists

## References

10. Bonjheer M, Lohr R, Solter o-Riveva M, Brown CC, Rother AM. Effect of tooth extraction on gingivostomatitis in cats: 95 cases (2000-2013). *J Am Vet Med Assoc*. 2015 Apr 15;236(8):1212-6. doi: 10.2460/javma.236.8.1212. PMID: 25739688.
11. Hennet P. Chronic Gingivitis Stomatitis in Cats: Long-Term Follow-up of 30 Cases Treated by Dental Extraction. *JVD*. 1997 Mar;14(1):25-21.
12. Bellei E, Dalla F, Mastelloni L, Pisori L, Jaechler M. Surgical therapy in chronic feline gingivostomatitis (FCGS). *Vet Res Commun*. 2008 Sep;32(suppl 1):S231-4. doi: 10.1007/s11259-008-9163-8. PMID: 18883967.
13. Shivam, Ramakrishna M, Prabhu M, Nagaraj L. A Case Series Analysis of Dental Extraction Outcome in Cats with Chronic Gingivostomatitis, CatVine Retrospective Disease. *Animals (Basel)*. 2021 Nov 9;11(11):3306. doi: 10.3390/ani11113306. PMID: 34826677; PMCID: PMC8421239.
14. Lommer M. Efficacy of cyclosporine for chronic, refractory stomatitis in cats: a randomized, placebo-controlled, double-blinded clinical study. *J Vet Dent*. 2013 Spring;3(1):18-17. doi: 10.1177/0898787513030000101. PMID: 23757820.
15. Harcourt PR, Camy GA, McCallie DM, Alboin M. Comparison of efficacy of a feline brand of feline calicivirus vaccine in cats with gingivitis and gingivostomatitis. *Am J Vet Res*. 2011 Aug;72(8):977-81. doi: 10.2460/ajvr.72.8.977. PMID: 21862039; PMCID: PMC3129176.
16. Matsuyama H, Tachibana T, Iwata Y, Sakurai O, Takahara D, Anzures A, Kagami A. Evaluation of the efficacy of the subcutaneous low molecular weight heparin in combination with oral prednisolone for feline chronic gingivostomatitis in feline calicivirus-positive cats. *Res Vet Sci*. 2018 Dec;117:51-58. doi: 10.1016/j.rvsc.2018.10.003. Epub 2018 Oct 12. PMID: 30159811.
17. Solter o-Riveva M, Hart IS, Mandin O, Vapnirky N, Arz J, B. Mesenchymal stromal cell therapy for feline chronic gingivostomatitis: a pilot study. *Front Vet Sci*. 2023 Apr 14;10:1171922. doi: 10.3389/fvet.2023.1171922. PMID: 37168097; PMCID: PMC10165997.

Cornell University Veterinary Specialists